

# Vitamin D Deficiency: Causes & Treatments

## Vitamin D Deficiency in Implant Dentistry: Link to Early Implant Failure and Biomaterial-Related Complications

*Richard J Miron<sup>1\*</sup>, Ana Paz<sup>2</sup>, Valerie Kanter<sup>3</sup>, Miguel Stanley<sup>2</sup>, Mark Bishara<sup>4</sup>, Yufeng Zhang<sup>5</sup>, Carlos Fernando Mourao<sup>6</sup>*

*<sup>1</sup>Department of Periodontology, School of Dental Medicine, University of Bern, Bern, Switzerland*

*<sup>2</sup>White Clinic, Research Department, Lisbon, Portugal*

*<sup>3</sup>Department of Endodontics, University of Southern California Los Angeles (UCLA), Los Angeles, California, USA*

*<sup>4</sup>West Bowmanville Family Dental, Private Practice, Toronto, Canada*

*<sup>5</sup>Department of Dental Implantology, School and Hospital of Stomatology, Wuhan University, Wuhan, China*

*<sup>6</sup>Department of Oral Surgery, Dentistry School, Fluminense Federal University, Niterói, Rio de Janeiro, Brazil*

*\*Correspondence to: Richard J Miron, Department of Periodontology, School of Dental Medicine, University of Bern, Bern, Switzerland*

*Email: richard.miron@zmk.unibe.ch*

### Abstract

Dental implants are generally considered a safe and highly predictable surgical procedure performed by many dental surgeons with the aim of replacing missing teeth. Yet to this day, a number of implants are lost every year for yet explained reasons. Dental implants remain one of the only transmucosal implant utilized in medicine; meaning they integrate directly into bone (a phenomenon called osseointegration) yet span into the oral cavity through transmucosal tissues. In this area, a number of bacteria co-exist with host living cells (primarily epithelial and immune cells) creating peri-implant pockets. Here an array of cytokines and highly active complex compounds are secreted and may reduce host defense/antibacterial properties. This book chapter discusses the importance and relevance of tissue homeostasis as it relates to oxidative stress. Furthermore, one of the most prominent vitamin deficiencies known to mankind, that of vitamin D, is discussed as a primary cause linked with early dental implant failure. Recommended doses and guidelines are provided with ongoing future research

presented as it relates to 6 week pre-surgical supplementation program aimed at reducing early implant failure.

## 1. Introduction

Vitamin D deficiency is a worldwide public health problem that spans across all age groups from children to adults. Naturally, as we age, our ability to absorb vitamin D is also decreased. The major source of vitamin D is directly from sunlight exposure with very few foods that naturally contain sufficient doses. Unfortunately, direct sunlight has tremendously decreased in modern society with the increased number of desk-related jobs. Epidemiological studies have now shown that roughly 70% of society is deficient [1].

Vitamin D deficiency is most known for its association in osteoporotic and menopausal women. Few realize however its drastic and substantial role in various other diseases. These include depression, dementia, Alzheimer's disease, asthma, cancer, cardiovascular disease, diabetes among others highlighted throughout this textbook. Vitamin D is essential for gastrointestinal calcium absorption, mineralization of osteoid tissue and maintenance of serum ionized calcium level. It is also important for other physiological functions, such as muscle strength, neuromuscular coordination, and hormone release [2]. More recently, vitamin D deficiency has also been associated with up to a 300% increase in dental implant failure and associations with other dental-related complications are increasing [3-12]. Optimizing levels prior to surgery therefore becomes fundamental for maximizing wound healing and this chapter discusses its association with dental implant-related failures and bone grafting complications.

## 2. Optimizing Vitamin D levels

Serum 25-hydroxy vitamin D (25-OHD) is the reliable marker of vitamin D status and a level below 20 ng/ml defines deficiency. Optimal levels above 30 ng/ml is required to maximize the bone health and non-skeletal benefits of vitamin D (**Table 1**). For individuals undergoing any type of dental related procedures, levels between 40-60 ng/ml are generally recommended since it is known that following a period of stress (simply a dental surgical intervention), levels may decrease substantially.

**Table 1:** Vitamin D concentrations in humans in both deficiency, optimal and toxic levels.

| Status            | Serum 25 OH    | Vitamin D Concentration |
|-------------------|----------------|-------------------------|
| Severe Deficiency | <10 ng/ml      | <25 nmol/liter          |
| Deficiency        | <20 ng/ml      | <50 nmol/l              |
| Insufficiency     | 21 – 29 ng/ml  | 50 – 74 nmol/l          |
| Sufficiency       | 30 – 100 ng/ml | 75 – 250 nmol/l         |
| Optimal           | 30 – 60 ng/ml  | 75 – 150 nmol/l         |
| Toxic             | >150 ng/ml     | >375 nmol/l             |
| Pre-surgery       | 40-60 ng/ml    | 100-150 nmol/l          |

Unfortunately, foods do not contain sufficient levels. Examples are Cod liver oil (400–1,000 IU/teaspoon), fresh caught salmon (600–1,000 IU/3.5 oz vitamin D3), tuna (236 IU/3.5 oz vitamin D3), egg yolk (20 IU/yolk vitamin D3 or D2), and fortified milk, cheese or yogurt (100 IU/3 oz, usually vitamin D3). These are low levels considering deficiency should be treated with 4000-6000 IU/day for a 6-8 week period to restore levels to sufficient values.

According to the American Association of Clinical Endocrinologists (AACE) and the American College of Endocrinology (ACE) guidelines it is recommended supplementation to maintain levels above 30 ng/ml [13]. The Endocrine society in the USA recommends achieving a concentration of more than 30 ng/ml (>75 nmol/L) of serum 25 (OH)D, and considers the optimal range 40-60 ng/ml (100-150 nmol/L). The Endocrine society also advocates an intake of 1500-2000 IU/day (37.5-50 µg) in adults, regarding that obese patients (BMI > 30 kg/m<sup>2</sup>) should take three times more the normal adult daily vitamin dose [13]. Unfortunately, epidemiological studies across United States has routinely shown that deficiencies of Vitamin D are typically found with approximately 70% of the population and this deficiency is only expected to increase as the population works more indoors. The following chapters describes the marked impact on dental implant failure as a result.

### 3. Dental-Related Complications

Vitamin D plays an important role in supporting the immune system and integration of various biomaterials. It is also relevant for decreasing general oxidative stress and minimizing additional inflammation caused by surgery. As expressed previously, Vitamin D is also involved in biomaterial integration and other metabolic process such as bone remodeling. Therefore, some complications had been related to vitamin D deficiency in the dental field.

In 2009, a first animal study investigated the role of Vitamin D on dental implant osseointegration [9]. Utilizing a rat model, implants were placed in both normal control and vitamin D-deficient animals and subject to implant push out tests as well as histological analysis. The push-out tests revealed an approximate 66% decrease in value in the vitamin D deficient group and also revealed significantly lower bone to implant contact as early as 14

days post-implant placement. It was concluded from this study that the effect of vitamin D deficiency was unexpectedly profound. It was further addressed that future clinical research would benefit patient care owing to these observations.

Following years of initial pre-clinical studies demonstrating the marked impact of vitamin D deficiency on osseointegration, additional clinical studies were then reported. These began initially as case reports. In 2014, Bryce and MacBeth reported that vitamin D deficiency was suspected as a causative factor in the failure of immediate implants [4]. In summary, it was reported that vitamin D deficiency was directly associated with early implant failure. It was also advised that the assessment of vitamin D prior to implant surgery be performed, especially in patients having undergone either long-term hospital care or a recent traumatic injury/event [4]. Additionally, in the same year, it was also noted that low vitamin D deficiency may be a risk factor for implant osseointegration and also bone graft infection [5].

In 2016, Fretwurst et al. reported that the unexpected implant removal in a dental university clinic were subject to much controversy for potential causes [6]. These random implants were often removed after only 15 days following placement and therefore patients were then sent for various blood analysis. It was found in each case report that extremely low serum vitamin D levels (serum vitamin D level  $<20 \mu\text{g/l}$ ) were reported in all cases. This study group described that after a six month period of healing and vitamin D supplementation levels were raised ( $>46 \mu\text{g/l}$ ), and implants were successful osseointegrated in all cases following adequate supplementation [6]. It was recommended that future randomized clinical trials be utilized to investigate the relationship between vitamin D deficiency and implant failure, osteoimmunology and early implant complications [6].

In 2017, Insua et al. wrote an extensive review article on the concept of peri-implant disease being driven by osteoimmunology, osteal macrophages and their related breakdown and maintenance [8]. An entire section was dedicated to Vitamin D and its correlation with lower bone to implant contact and potential complications and peri-implant bone loss over time. Furthermore, the immune system was also discussed during homeostasis of peri-implant tissue/osseointegration [8].

In 2019, Mangano et al. published a retrospective study whereby nearly 2000 implants were investigated in nearly 1000 patients (**Table 2**) [7]. To date, this represents the largest study on the topic where implant failure rates were gathered along with other known complications associated with dental implant failure such as smoking and generalized periodontitis. In that study, it was reported that heavy smoking (defined as 15 cigarettes per day) was found to be associated with approximately a 50% increase in early implant failure. Similar, generalized periodontitis was also associated with an approximate 50% increase in dental implant failure. Interesting, severe vitamin D deficiency (defined as serum levels  $<10\text{ng/mL}$ ) was reported

at nearly a 300% increase in overall implant failure rates when compared to controls [7]. The conclusions from this study demonstrate the need for adequate testing, prevention and supplementation prior to dental implant placement and maintenance [7].

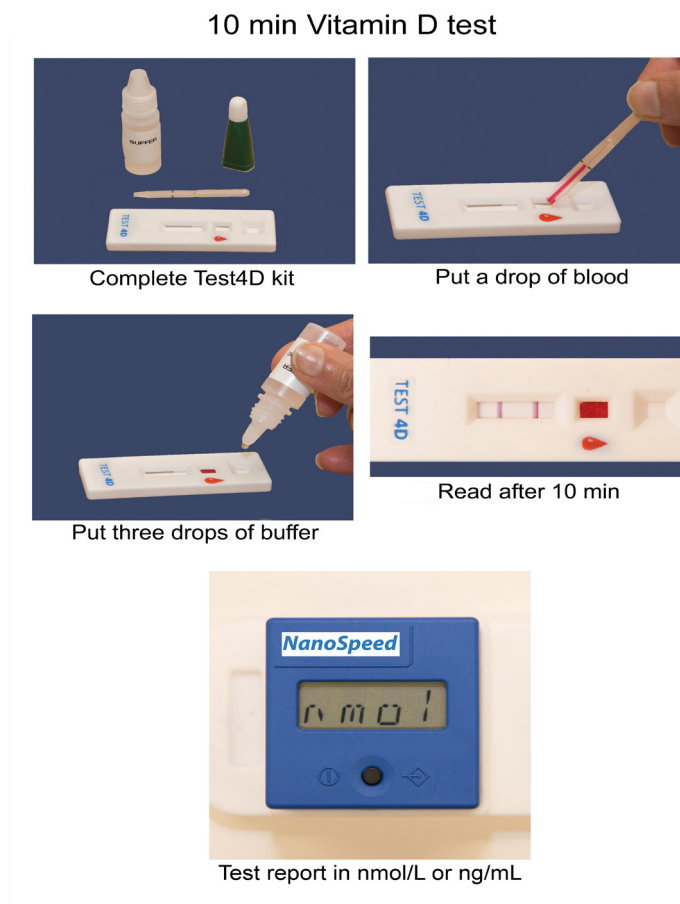
**Table 2:** Number Of Patients, Early Dental Implant Failures, And Failure Rates Within Groups, And Differences Among Groups (Chi-Squared Test)

|                                       |            |           |              |              |
|---------------------------------------|------------|-----------|--------------|--------------|
| <b>Overall</b>                        | <b>885</b> | <b>35</b> | <b>3.9%</b>  |              |
| <b>Gender</b>                         |            |           |              |              |
| <b>Males</b>                          | <b>455</b> | <b>18</b> | <b>3.9%</b>  |              |
|                                       |            |           |              | <b>0.998</b> |
| <b>Females</b>                        | <b>430</b> | <b>17</b> | <b>3.9%</b>  |              |
| <b>Age at surgery</b>                 |            |           |              |              |
| < 40 years                            | <b>100</b> | <b>5</b>  | <b>5.0%</b>  |              |
| 40-60 years                           | <b>412</b> | <b>15</b> | <b>3.6%</b>  | <b>0.832</b> |
| >60 years                             | <b>373</b> | <b>15</b> | <b>4.0%</b>  |              |
| <b>Smoking habit</b>                  |            |           |              |              |
| Heavy smokers (>15 cigarettes/day)    | <b>98</b>  | <b>6</b>  | <b>6.1%</b>  |              |
| Light smokers (1-15 cigarettes/day)   | <b>184</b> | <b>8</b>  | <b>4.3%</b>  | <b>0.473</b> |
| Non smokers                           | <b>603</b> | <b>21</b> | <b>3.4%</b>  |              |
| <b>History of periodontal disease</b> |            |           |              |              |
| Generalized periodontitis             | <b>97</b>  | <b>6</b>  | <b>6.1%</b>  |              |
| Localized periodontitis               | <b>218</b> | <b>10</b> | <b>4.5%</b>  | <b>0.386</b> |
| No periodontitis                      | <b>570</b> | <b>19</b> | <b>3.3%</b>  |              |
| <b>Vitamin D serum levels</b>         |            |           |              |              |
| <10 ng/ml                             | <b>27</b>  | <b>3</b>  | <b>11.1%</b> |              |
| 10-30 ng/ml                           | <b>448</b> | <b>20</b> | <b>4.4%</b>  | <b>0.105</b> |
| >30 ng/ml                             | <b>410</b> | <b>12</b> | <b>2.9%</b>  |              |

\*Chi-squared test, with statistically significant difference set at  $p < 0.05$

#### 4. Testing Vitamin D Levels

Standard vitamin D tests are routinely performed by measuring serum vitamin D levels in whole blood serum. Naturally this provides an adequate analysis of blood vitamin D levels however the issue is the inconvenience to the patient seeking routine dental work. NanoSpeed has since developed a novel vitamin D test kit that is based on a simple finger prick test (**Figure 1**). Within 10 minutes, vitamin D levels can be reported in office with a simple finger prick test. The easy to use test is cost effective as compared to competing technologies that require venous blood.



**Figure 1:** Step-by-step instructions to utilizing the 10 minute Vitamin D detection system from a simple finger-prick test.

The technology is based on the principle of a competitive immunoassay. The assay is based on the competition for 25-OH Vitamin D present in blood/serum sample and Vitamin D present on the test line for fixed number of antibody-gold conjugate. Depending upon the concentration of Vitamin D in blood/serum, there will be varying number of free antibody-gold conjugate molecule that will bind to Vitamin D on the test strip and will show a colored line in the test line zone.

During the specimen preparation, the blood sample (10ul) is placed on the assay (red mark) according to Figure 1. Then 3 full drops of the Chase buffer is added into the square buffer well of the cassette. Within 10 minutes, the Vitamin D measurement may be obtained.

Owing to the technological advancement, it therefore becomes possible to utilize the equipment prior to dental implant placement or bone grafting surgery to determine optimal levels to minimize implant/graft failure. When deficient, it is clear patients need a solution and typically supplementation is recommended as highlighted below.

## **5. Supplemental Recovery Program – The Science behind Dental Healing**

Owing to the impact of vitamin D deficiency-related complications and failures in dentistry, one key component of a supplemental recovery program (DentaMedica®, San Diego, California) is that patients adequately reach optimal levels of vitamin D and and



related co-factors prior to dental surgery (**Figure 2**). Bone-related support includes Vitamin K, magnesium, calcium, manganese, boron amongst others. The 6-week program is designed to boost levels prior to surgery (6000 IU/day) for 4 weeks with 2 weeks of maintenance post-surgery. Noteworthy, for patients over 65 years of age, for diabetics, smokers, or patients with reported immune-compromised or on corticosteroids, a 12 week program is recommended (8 weeks prior to surgery and 4 weeks post-surgery).



**Figure 2:** DentaMedica's 6 week recovery program aimed at optimizing vitamin D levels and antioxidant levels prior to implant placement.

## 6. Antioxidants and Their Role In Wound Healing

Several factors can impair wound healing such as oxygenation defects, aging, and overall stress. Furthermore, a number of other factors such as infection found in periodontal disease, diabetes, alcohol overuse, smoking and impaired nutritional status may also result in deficient wound healing. Growing evidence suggests that reactive oxygen species (ROS) are crucial regulators of several phases of wound healing. In recent years, ROS has gained attention because of their central role to the progression of many inflammatory diseases [14]. Excessive production of ROS or impaired ROS detoxification causes oxidative damage, which has been shown to be a main cause of non-healing chronic wounds and tissue degeneration [15,16].

In simple terms, ROS are oxygen free radicals and other non-radical oxygen derivatives involved in tissue degradation [17]. They are produced during normal cellular metabolism by cells in most tissues. To combat oxidative stress, all cells in the body are equipped with an intrinsic store of molecules known as “antioxidants” which prevents tissue damage [18]. When this balance is shifted however, high levels and activity of ROS causes DNA damage, protein damage, and lipid peroxidation. This in term leads to impaired wound healing and many long-term chronic degenerative diseases and whole body tissue inflammation, are linked to common diseases such as dementia and various cancers.

Unfortunately a large percentage of the population today suffers from vitamin and mineral deficiencies which help increase antioxidant levels. In particular, absorption of vitamins and minerals is decreased with poor diet, aging, diabetics, those treated with immunosuppressive drugs, as well as chemo- or radiotherapy. Furthermore, alcohol consumption [19], smoking

[20] and hypertension [21] are all associated with higher rates of vitamin deficiencies and/or oxidative stress and its associated with oral health diseases such as periodontitis.

Supplementation with low molecular weight antioxidants and ROS-detoxifying enzymes has become vital for many individuals with deficiencies [22]. There are 2 categories of antioxidants including 1) enzymatic antioxidants such as superoxide dismutase (SOD), catalase (CAT), glutathione peroxidase/reductase, DNA repair enzymes, and various metal ion sequestrators. Secondly, scavenging antioxidants or chain breaking antioxidants such as ascorbic acid (vitamin C), carotenoids (including retinol-vitamin A), uric acid,  $\alpha$ -tocopherol (vitamin E), coenzyme Q, and polyphenols (flavonoids) are all potent antioxidants commonly associated with improved wound healing.

In an effort towards the maintenance of optimal levels of the aforementioned antioxidants (as well as the overall desire for patients to improve general health), additional supplementation with vitamins and minerals to treat nutritional deficiencies have become routine in modern culture.

## 7. Overall Antioxidant Deficiency in Modern Culture

Antioxidants in the diet have some remarkable benefits and valuable properties that play an irreplaceable role in the maintenance of periodontal health, bone physiology and soft tissue wound healing. Epidemiological studies from the United States has demonstrated that vitamin deficiencies range dramatically among the population (**Table 3**).

**Table 3:** Vitamin Deficiency in the General US population

|                           |
|---------------------------|
| Vitamin A = 34% deficient |
| Vitamin C = 25% deficient |
| Vitamin D = 70% deficient |
| Vitamin E = 60% deficient |
| Calcium = 38% deficient   |
| Magnesium = 45% deficient |

As a result, it is clear that prior to any type of surgery, vitamin recovery programs are indispensable to restore levels in patients prior to surgical procedures since failure may occur as a result of any of the above-mentioned deficiencies. Importantly, Vitamin D deficiency in particular has been shown to be linked to a much greater implant failure rate in dentistry, and is also the highest known vitamin deficiency in mankind worldwide. As highlighted throughout the rest of this book, vitamin D deficiency is also linked to a number of other health issues including depression, Alzheimer's disease, asthma, alopecia, cardiovascular disease, cancer, diabetes, hypertension, multiple sclerosis, Parkinson's disease, rickets, among other diseases.



## 8. Necessary Vitamins/Minerals for Healing and Recovery

**Vitamin D** is an extremely important vitamin for bone metabolism and is well known for its role in calcium homeostasis as previously mentioned. It also acts as a powerful antioxidant with anti-inflammatory activity because it acts directly on immune cell cytokine expression [23]. Unfortunately, it is majorly synthesized in the human body following sun exposure. With the increasing population being interior and the number of desk jobs continuously rising, it is one of the most prevalent vitamin deficiencies known to man worldwide. Unfortunately, foods in general have extremely low levels and supplementation therefore becomes a requirement when deficiency is present.

**Vitamin C** plays a significant role in periodontal health and maintenance. Vitamin C is a potent antioxidant which has a primary function as a radical scavenger [24] and is required for the synthesis of collagen hydroxylation in humans [24]. It also contributes to immune defense by supporting various cellular functions of both the innate and adaptive immune system. Vitamin C supports epithelial barrier function against pathogens and promotes the oxidant scavenging activity of the soft tissues, thereby potentially protecting against environmental oxidative stress by ultimately killing the microbia. Vitamin C deficiency results in impaired immunity and higher susceptibility to infections. Furthermore, infections significantly impact on vitamin C levels due to enhanced inflammation and metabolic requirements [25].

Vitamin C is rapidly depleted and oxidized within the extracellular fluids during oxidative stress [26]. It is especially important for bone forming osteoblasts to lay new bone matrix. Sources of vitamin C include natural fruits and vegetables such as gooseberry, broccoli, kiwi, grapefruits, citrus fruits, cauliflower, strawberries, pineapple, cherries, and potatoes. It is recommended to eat high levels prior to dental surgery.

**Flavonoids** are polyphenolic compounds found in plants known to contain potent antioxidant, anti-inflammatory, anti-allergic, antiplatelet, and antitumor activities [27]. It also has a positive effect against diverse diseases such as cancer, neurodegenerative or cardiovascular disease [28]. There exists a potent synergistic relationship between flavonoids and vitamin C as a powerful antioxidant combo [29]. Flavonoids also help to protect blood vessels from rupture or leakage. A popular source of flavonoids is green tea. Other sources include parsley, onions, blueberries and other berries, bananas, citrus fruits, Ginkgo biloba, red wine, sea buckthorns, and dark chocolates (with a cocoa content of >70%).

**B-Vitamins:** **Vitamin B1** (also called thiamin), **Vitamin B2** (also called riboflavin) are both vitamins that help convert food into energy. **Vitamin B1** is a hydrosoluble vitamin that plays a role in several biological processes mainly in glucose metabolism [30]. **Vitamin B2** helps maintain eyesight. **Vitamin B12** helps regulate the nervous system and plays a role in growth and red blood cell formation. It is found primarily in meat and dairy product. **Vitamin**

**B6** (also called pyridoxine) helps the body fight infections. It is primarily found in chickpeas, tuna, salmon, whole grains and cereals, beef liver, ground beef and chicken breast. **Biotin** is a water-soluble vitamin that's a part of the vitamin B family that also helps convert certain nutrients into energy. It also plays an important role in the health of your hair, skin, and nails.

**Carotenoids** are a set of naturally colored pigments. **Vitamin A** is one of the major carotenoids. They are antioxidant in nature and have protective effects on vitamins C and E. They also show synergistic effects by scavenging reactive nitrogen species. Beta-Carotene is the main source of vitamin A in the diet. Carotenoids have a significant influence on other antioxidants, and hence they are considered vital in antioxidant defense mechanisms. Sources include tomatoes, apricots, guavas, watermelons, papayas, and pink grapefruits.

**Magnesium** is a cofactor in more than 300 enzyme systems that regulate diverse biochemical reactions in the body, including protein synthesis, muscle and nerve function, blood glucose control, and blood pressure regulation [31, 32]. Magnesium is also required for energy production, oxidative phosphorylation, and glycolysis. It contributes to the structural development of bone and is required for the synthesis of DNA, RNA, and the antioxidant glutathione. Magnesium also plays a role in the active transport of calcium and potassium ions across cell membranes. Mostly consumed in nuts, almonds, cashews, peanuts and spinach [32].

**Zinc** is an essential trace element (micronutrient) which plays important roles in human physiology. Zinc is a cofactor for many metalloenzymes required for cell membrane repair, cell proliferation, growth and immune system function. The pathological effects of zinc deficiency include the occurrence of skin lesions, growth retardation, impaired immune function and compromised wound healing [33].

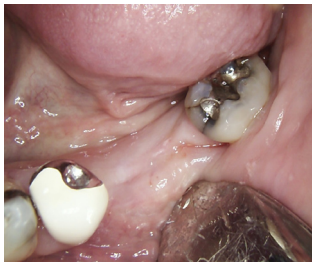**Manganese** is predominantly stored in the bones, liver, kidney, and pancreas and provides a role in the formation of connective tissue, bones, blood-clotting factors, and sex hormones. It assists in fat and carbohydrate metabolism, calcium absorption, and blood sugar regulation.

**Selenium** is yet another powerful antioxidant that fights oxidative stress and helps defend the body from chronic diseases. In addition to the aforementioned antioxidants, there are a number of other micronutrients and macronutrients, which may play a significant role in periodontal health and disease prevention. All recovery programs should provide antioxidants as their major beneficial component in the prevention of disease and implemented wound healing.

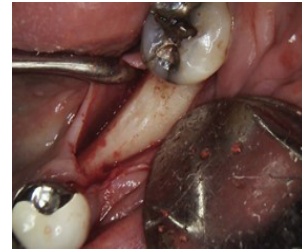## 9. Case Report of Implant Failure as a Suspected Result of Vitamin D Deficiency

Routinely dental implants are placed with long-term success rates above 90-95% [34-

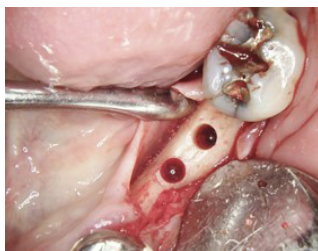
37]. Yet for relatively unknown reasons, a small percentage of implants are lost each year with yet explained findings. **Figure 3** demonstrates an initial ridge in a 73 year old male patient with sufficient bone ridge width for implant placement. The patient was not on any medication and was considered healthy. Following midcrestal flap elevation, a bone reduction was performed to allow adequate width for implant placement with 1-2 mm of remaining width on the buccal and lingual (**Figure 4**). Note the excellent ridge width. **Figure 5** demonstrating the implant osteotomies with adequate bone width on either side. Following implant placement at torque values of 40 N.cms (**Figure 6**), soft tissue closure was obtained and the implant was advised to maintain hygiene and salt water rinsing following meals (**Figure 7**). A peri-apical X-ray was taken following implant placement demonstrating adequate bone levels (**Figure 8**).



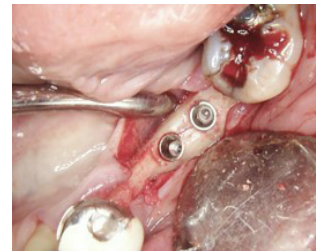
**Figure 3:** Mandibular ridge missing 2 posterior teeth. Ridge width demonstrates adequate bone width.



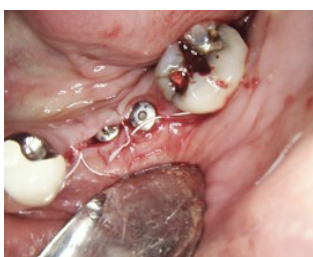**Figure 4:** Following mid-crestal flap elevation and bone reduction, adequate bone width is observed clinically.



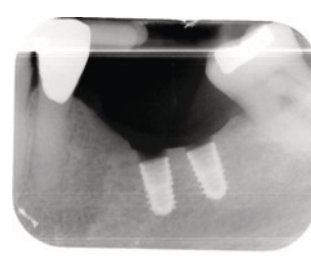
**Figure 5:** Implant osteotomies created.



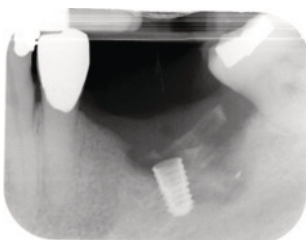
**Figure 6:** Implant placement with adequate bone width around both implants.



**Figure 7:** Soft tissue closure.



**Figure 8:** Peri-apical X-ray taken immediately after surgery demonstrating excellent implant placement.



**Figure 9:** 1 month post-op patient presents with implant mobility. Note the radiolucency around both implants which were both removed for yet known reasons. (Case performed by Dr. Mark Bishara)

At the 2 week recall, suture removal was performed and patient was advised to be seen 1 month later. At 1 month post-op, a subsequent peri-apical X-ray was taken where severe bone loss was noted around the implant and clinical mobility was observed (**Figure 9**). The implants were therefore removed and the patient was sent for medical analysis. This case highlights a typical case whereby simple osseointegration is expected in a relatively straightforward case yet unexplained early implant failure occurred.

Upon testing of a full blood workup, the main finding was the patient's low vitamin D levels. The patient reported levels of vitamin D deficiency. The patient was then supplemented with a 12 week recovery program of supplements (DentaMedica®) and implant placement was successful thereafter. This case represents a standard recovery program and timeline following early implant failure for yet known reasons to promote local healing and recovery of vitamin and mineral levels.

## **10. Patient Testing And Supplementation**

Owing to recent evidence suggesting a strong correlation between vitamin D deficiency and early implant failure, vitamin D testing pre-bone grafting and pre-implant placement has therefore been recommended. While blood work is not always common/available within a dental office, the ability to adequately test vitamin D levels within 10 minutes with a simple finger prick test becomes a highly valuable tool within dental offices. Upon discovery of low patient vitamin D levels, it becomes essential to supplement patients adequately prior to implant placement or bone grafting procedures. Another alternative is the use of supplementation prior to implant surgery and bone graft surgery. A minimum 4 week supplementation program is recommended to elevate all vitamin and mineral levels prior to surgery followed by 2 weeks post-op.

## **11. Conclusion**

The present book chapter highlights the effects of vitamin D deficiency on early implant failure and bone graft complications. Vitamin D remains one of the most highly prevalent vitamin deficiencies known to man and a direct link with bone tissue homeostasis and remodeling has been reported in the literature. Noteworthy, vitamin D is also linked with the immune system whereby introduced biomaterials into the body (especially in bone) such as dental implants may be compromised when vitamin D deficiency is observed. This chapter highlights the fact that recent studies have demonstrated a marked and significant additional increase in early failure of dental implants roughly 300% higher than standard healthy implants. Furthermore, discussion over supplementation and a recovery program is discussed as a means to assist patients in the recovery both pre-surgically as well as in the recovery of patients demonstrating low vitamin D levels.



## 12. References

1. Woo YS, Kim S, Jeong JH, Jung YE, Kim MD, Bahk WM. Vitamin D Deficiency/Insufficiency among Inpatients with Depressive Symptoms. *Clinical psychopharmacology and neuroscience : the official scientific journal of the Korean College of Neuropsychopharmacology* 2019;17:121-4.
2. Wimalawansa SJ, Razzaque MS, Al-Daghri NM. Calcium and vitamin D in human health: Hype or real? *The Journal of steroid biochemistry and molecular biology* 2018;180:4-14.
3. Akhavan A, Noroozi Z, Shafiei AA, Haghighat A, Jahanshahi GR, Mousavi SB. The effect of vitamin D supplementation on bone formation around titanium implants in diabetic rats. *Dental research journal* 2012;9:582-7.
4. Bryce G, MacBeth N. Vitamin D deficiency as a suspected causative factor in the failure of an immediately placed dental implant: a case report. *Journal of the Royal Naval Medical Service* 2014;100:328-32.
5. Choukroun J, Khoury G, Khoury F, Russe P, Testori T, Komiyama Y, Sammartino G, Palacci P, Tunali M, Choukroun E. Two neglected biologic risk factors in bone grafting and implantology: high low-density lipoprotein cholesterol and low serum vitamin D. *The Journal of oral implantology* 2014;40:110-4.
6. Fretwurst T, Grunert S, Woelber JP, Nelson K, Semper-Hogg W. Vitamin D deficiency in early implant failure: two case reports. *Int J Implant Dent* 2016;2:24.
7. Guido Mangano F, Ghertasi Oskouei S, Paz A, Mangano N, Mangano C. Low serum vitamin D and early dental implant failure: Is there a connection? A retrospective clinical study on 1740 implants placed in 885 patients. *Journal of dental research, dental clinics, dental prospects* 2018;12:174-82.
8. Insua A, Monje A, Wang HL, Miron RJ. Basis of bone metabolism around dental implants during osseointegration and peri-implant bone loss. *Journal of biomedical materials research Part A* 2017;105:2075-89.
9. Kelly J, Lin A, Wang CJ, Park S, Nishimura I. Vitamin D and bone physiology: demonstration of vitamin D deficiency in an implant osseointegration rat model. *Journal of prosthodontics : official journal of the American College of Prosthodontists* 2009;18:473-8.
10. Liu W, Zhang S, Zhao D, Zou H, Sun N, Liang X, Dard M, Lanske B, Yuan Q. Vitamin D supplementation enhances the fixation of titanium implants in chronic kidney disease mice. *PloS one* 2014;9:e95689.
11. Mangano F, Mortellaro C, Mangano N, Mangano C. Is Low Serum Vitamin D Associated with Early Dental Implant Failure? A Retrospective Evaluation on 1625 Implants Placed in 822 Patients. *Mediators of inflammation* 2016;2016:5319718.
12. Xiong Y, Zhang Y, Guo Y, Yuan Y, Guo Q, Gong P, Wu Y. 1alpha,25-Dihydroxyvitamin D3 increases implant osseointegration in diabetic mice partly through FoxO1 inactivation in osteoblasts. *Biochemical and biophysical research communications* 2017;494:626-33.
13. Pludowski P, Holick MF, Grant WB, Konstantynowicz J, Mascarenhas MR, Haq A, Povoroznyuk V, Balatska N, Barbosa AP, Karonova T, Rudenka E, Misiorowski W, Zakharova I, Rudenka A, Lukaszkiwicz J, Marcinowska-Suchowierska E, Laszcz N, Abramowicz P, Bhattoa HP, Wimalawansa SJ. Vitamin D supplementation guidelines. *The Journal of steroid biochemistry and molecular biology* 2018;175:125-35.
14. Mittal M, Siddiqui MR, Tran K, Reddy SP, Malik ABJA, signaling r. Reactive oxygen species in inflammation and tissue injury. *2014;20:1126-67.*
15. Cano Sanchez M, Lancel S, Boulanger E, Neviere R. Targeting Oxidative Stress and Mitochondrial Dysfunction in the Treatment of Impaired Wound Healing: A Systematic Review. *Antioxidants (Basel, Switzerland)* 2018;7.
16. Wei W, Liu Q, Tan Y, Liu L, Li X, Cai L. Oxidative stress, diabetes, and diabetic complications. *Hemoglobin* 2009;33:370-7.

17. Lushchak VIJC-bi. Free radicals, reactive oxygen species, oxidative stress and its classification. 2014;224:164-75.
18. Sies HJEPT, Integration. Oxidative stress: oxidants and antioxidants. 1997;82:291-5.
19. Park JB, Han K, Park YG, Ko YJJop. Association between alcohol consumption and periodontal disease: the 2008 to 2010 Korea National Health and Nutrition Examination Survey. 2014;85:1521-8.
20. Jang A-Y, Lee J-K, Shin J-Y, Lee H-YJK jofm. Association between smoking and periodontal disease in Korean adults: the fifth Korea National Health and Nutrition Examination survey (2010 and 2012). 2016;37:117.
21. Ahn YB, Shin MS, Byun JS, Kim HDJJocp. The association of hypertension with periodontitis is highlighted in female adults: results from the Fourth Korea National Health and Nutrition Examination Survey. 2015;42:998-1005.
22. Schafer M, Werner S. Oxidative stress in normal and impaired wound repair. Pharmacological research 2008;58:165-71.
23. Anand N, Chandrasekaran S, Rajput NSJJoISoP. Vitamin D and periodontal health: Current concepts. 2013;17:302.
24. Wilson JXJARN. Regulation of vitamin C transport. 2005;25:105-25.
25. Carr AC, Maggini S. Vitamin C and Immune Function. Nutrients 2017;9.
26. Frei B, England L, Ames BNJPotNAoS. Ascorbate is an outstanding antioxidant in human blood plasma. 1989;86:6377-81.
27. Vinson JA, Jang JJJomf. In vitro and in vivo lipoprotein antioxidant effect of a citrus extract and ascorbic acid on normal and hypercholesterolemic human subjects. 2001;4:187-92.
28. Faggio C, Sureda A, Morabito S, Sanches-Silva A, Mocan A, Nabavi SF, Nabavi SM. Flavonoids and platelet aggregation: A brief review. European journal of pharmacology 2017;807:91-101.
29. Tapas A, Sakarkar D, Kakde RJTJPR. A review of flavonoids as nutraceuticals. 2008;7:1089-99.
30. Polegato BF, Pereira AG, Azevedo PS, Costa NA, Zornoff LAM, Paiva SAR, Minicucci MF. Role of Thiamin in Health and Disease. Nutrition in clinical practice : official publication of the American Society for Parenteral and Enteral Nutrition 2019.
31. Food, Nutrition Board IoMJSCotSEoDRI. Dietary reference intakes for calcium, phosphorus, magnesium, vitamin D, and fluoride. National Academy Press Washington, DC; 1997.
32. Coates PM, Paul MC, Blackman M, Blackman MR, Cragg GM, Levine M, White JD, Moss J, Levine MA. Encyclopedia of Dietary Supplements (Online): CRC Press; 2004.
33. Lin PH, Sermersheim M, Li H, Lee PHU, Steinberg SM, Ma J. Zinc in Wound Healing Modulation. Nutrients 2017;10.
34. Moraschini V, Poubel LdC, Ferreira V, dos Sp Barboza EJIjoo, surgery m. Evaluation of survival and success rates of dental implants reported in longitudinal studies with a follow-up period of at least 10 years: a systematic review. 2015;44:377-88.
35. Chrcanovic BR, Albrektsson T, Wennerberg AJJod. Smoking and dental implants: a systematic review and meta-analysis. 2015;43:487-98.
36. Del Fabbro M, Wallace SS, Testori TJJoP, Dentistry R. Long-term implant survival in the grafted maxillary sinus: a systematic review. 2013;33.



37. Slagter KW, den Hartog L, Bakker NA, Vissink A, Meijer HJ, Raghoobar GMJJop. Immediate placement of dental implants in the esthetic zone: a systematic review and pooled analysis. 2014;85:e241-e50.